

## Case Report

# An unusual etiology of Globus pharyngeus – the Killian–Jamieson diverticulum

Geethu Rachel Iype<sup>1</sup>, Bichu Jacob<sup>2</sup>, Danny Jose Titus<sup>3</sup>, Sujith Philip<sup>1</sup>

Departments of <sup>1</sup>Gastrointestinal Surgery, <sup>2</sup>Oral and Maxillofacial Surgery, <sup>3</sup>Radiodiagnosis, Believers Church Medical College Hospital, Thiruvalla, Kerala, India.



### \*Corresponding author:

Sujith Philip,  
Department of Gastrointestinal  
Surgery, Believers Church  
Medical College Hospital,  
Thiruvalla, Kerala, India.

drsujithphilip@gmail.com

Received: 27 February 2023

Accepted: 26 June 2024

Published: 26 August 2024

DOI

10.25259/GJHSR\_19\_2023

Quick Response Code:



## ABSTRACT

Mucosal outpouching between the muscles of the pharynx and proximal esophagus are known as pharyngoesophageal diverticula. These are rare acquired causes of dysphagia and globus sensation in the middle aged and elderly. This report is about a gentleman who presented with globus pharyngeus. Globus pharyngeus or feeling of lump in throat is a common presenting complaint. This is usually due to gastroesophageal reflux disease or psychosocial factors including stress in most cases. However, in this case on investigation, he was found to have a symptomatic Killian–Jamieson diverticulum. This is one of the rarer types of cricopharyngeal diverticula and a cause of globus pharyngeus. He was treated surgically by a transcervical stapled diverticulectomy. A cricopharyngeal diverticulum should be thought of in the differential diagnosis of cause of globus pharyngeus.

**Keywords:** Killian–Jamieson diverticulum, Globus pharyngeus, Globus sensation, Diverticulectomy

## INTRODUCTION

Globus pharyngeus or Globus sensation is not an uncommon presenting complaint and experienced by up to 45% of the population.<sup>[1]</sup> Among the common causes are gastroesophageal reflux disease, hiatus hernia, sinusitis, smoking, stress, and anxiety.<sup>[2]</sup> After history and neck examination, it is usually managed conservatively based on its etiology. However, when patients do not respond to this, rarer causes should be thought of.

Mucosal outpouching between the muscles of the pharynx and proximal esophagus are known as pharyngoesophageal diverticula (POD). These are rare acquired causes of dysphagia and Globus sensation in the middle aged and elderly. Killian–Jamieson diverticulum (KJD) is a rare type of pharyngoesophageal diverticulum that arises inferior to cricopharyngeus muscle and lateral to the longitudinal muscles of the cervical esophagus.<sup>[3]</sup> This weak region, known as the Killian–Jamieson space, has the branches of the recurrent laryngeal nerve (RLN) passing through it. Akin to Zenker's diverticulum (ZD) and KJDs are thought to be acquired pulsion diverticula that arise due to a combination of age-related changes on the musculature of the esophagus and swallowing dysfunction. Treatment is usually by surgery (diverticulectomy or diverticulopexy) or endoscopic resection. Although there are now reports of endoscopic repairs, it has increased risk of injury to the RLN.<sup>[4]</sup>

This is an open-access article distributed under the terms of the Creative Commons Attribution-Non Commercial-Share Alike 4.0 License, which allows others to remix, transform, and build upon the work non-commercially, as long as the author is credited and the new creations are licensed under the identical terms.

©2024 Published by Scientific Scholar on behalf of Global Journal of Health Science and Research

## CASE REPORT

A 67-year-old gentleman presented with a painless sensation of a swelling in the throat and food getting stuck in the throat while swallowing (Globus pharyngeus or Globus sensation) of 1 year duration. He also had history of recurrent respiratory tract infection. He used to smoke one packet of local cigarette (Beedi) per day. He was initially advised to stop smoking since it is a common cause of globus. Since he had these symptoms along with dyspepsia, he was treated with proton pump inhibitors also. However, despite these, his symptoms persisted.

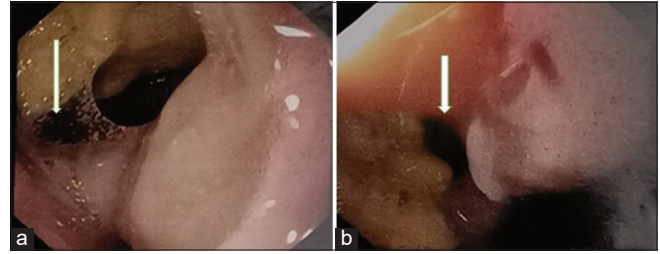
Hence, an upper gastrointestinal endoscopy was done for further evaluation. This revealed an esophageal diverticulum at 16 cm from the incisors, with food particles within [Figure 1]. Barium swallow showed a large localized outpouching arising from the anterior and left lateral aspect of the esophagus, at C7/D 1 level, with pooling of barium within [Figure 2]. Based on the radiological and endoscopic features, this was diagnosed as a KJD. The recurrent respiratory infections were thought to be due to regurgitation from the diverticulum. A contrast-enhanced computed tomography (CECT) of the neck was taken to further delineate the anatomy of the pouch and its relations to the neck vasculature before surgery.

After pre-operative pulmonary rehabilitation which included incentive spirometry, bronchodilators, and treatment of respiratory infection, he was planned for surgery. He underwent a transcervical esophageal diverticulectomy of the KJD.

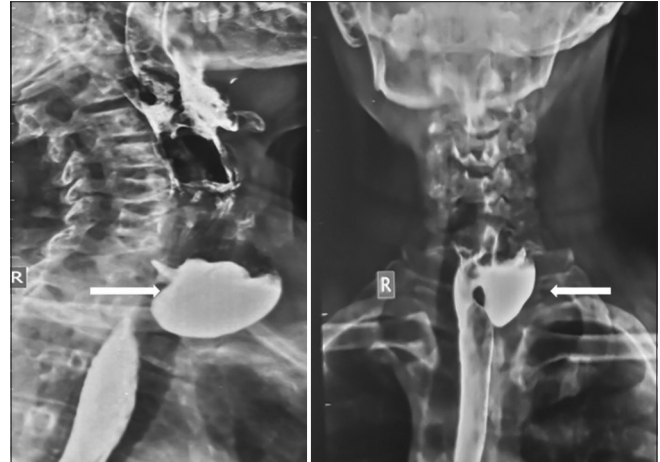A skin crease incision of the left anterolateral neck was made with the patient in supine and neck hyperextended. Subplatysmal flaps were created superiorly and inferiorly. Dissection was continued along the anterior border of sternomastoid and it was retracted laterally to expose the carotid sheath. The strap muscles on the left were divided along with omohyoid and the facial vein was identified, clipped, and divided close to the junction with internal jugular vein (IJV) to improve exposure. The carotid and IJV were retracted laterally to expose the diverticulum. There were dense post-inflammatory adhesions of surrounding tissues to the diverticulum. These were separated and the dissection was advanced toward the neck of the sac. The esophagus position was confirmed by palpating the Ryle's tube. The RLN was found lying parallel and on the anterior surface of the neck of the diverticulum. It was dissected toward the esophagus and the diverticulum was stapled just lateral to it, with TA 45 3.5 mm staplers and adventitia over sewn with 4-0 polypropylene [Figures 3 and 4].

A positive oral contrast dye study was normal and he was started on oral feeds and discharged on day 5.

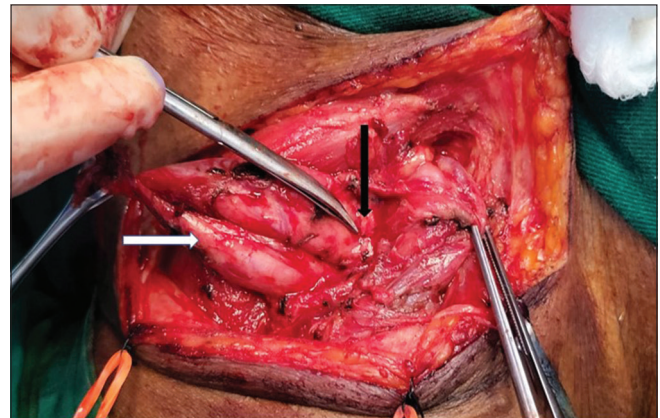
He had an uneventful post-operative recovery period with no hoarseness of voice or difficulty in swallowing. During



**Figure 1:** (a and b) Endoscopic picture showing esophageal lumen (white arrow) and diverticulum (white arrow).



**Figure 2:** Barium swallow-lateral and anteroposterior view showing pooled barium in an outpouching anterior and left lateral to the esophagus as indicated by white arrows.

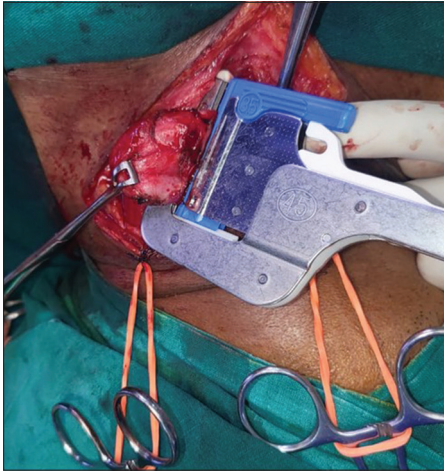


**Figure 3:** Intraoperative photograph showing the dissected Killian–Jamieson diverticulum (white arrow) and left recurrent laryngeal nerve before diverticulectomy (black arrow).

follow-up, his recurrent respiratory infection and globus sensation had subsided.

## DISCUSSION

POD are classified based on the point of origin in relation to the pharyngeal muscles and spaces. The most common



**Figure 4:** Intraoperative photograph of Killian's diverticulum being stapled.

among them, the ZD arises from a space located between the cricopharyngeus and thyropharyngeus. The less common KJD arises inferior and lateral to the cricopharyngeus and this report is regarding the same. The rarest among the POD is the Laimer's diverticulum, arising in the midline posteriorly, below the cricopharyngeus in the Laimer–Hackerman's space.<sup>[5]</sup>

First described in 1983, KJD or proximal lateral cervical diverticulum is a rare pulsion diverticulum of the cervical esophagus through the Killian–Jamieson space and distinguished from ZD based on its location.<sup>[6,7]</sup> It is usually left-sided and rarely bilateral. It is more common in middle aged women, less symptomatic, and smaller in dimensions than the ZD. Suprasternal dysphagia is the most common symptom, with cough and aspiration pneumonia being usually rare, probably due to its location below a functioning cricopharynxes. Globus pharyngeus is a rare presentation of KJD and due to increase in size of the diverticulum as demonstrated in this case. Usually, the large the diverticula, more were the symptoms.<sup>[8]</sup>

The treatment of KJD is mostly surgical. Among the approaches transcervical diverticulectomy, endoscopic diverticulotomy and diverticulopexy have been described as with ZD. While some authors have chosen to combine with cricopharyngeal myotomy, others authors deem it unnecessary due to its location with respect to the muscle. Transcervical diverticulectomy is preferable due to the close association of the RLN with the neck of the diverticulum. The risk of direct or indirect thermal injury to the nerve is much higher with endoscopic approach than with ZD.<sup>[4]</sup> Diverticulopexy is best reserved for those with poor performance status. Complications documented after surgery include recurrence and delayed staple line leak with cervical abscess formation. In the present case due to the above reasons, we chose a transcervical diverticulectomy. Due to probable recurrent

infections, there were dense post-inflammatory changes around the diverticulum. The RLN was identified with some difficulty due to the peridiverticular inflammatory changes and preserved.

Since KJD is a pulsion diverticulum only the mucosa and submucosa which are involved in the diverticulum. It comes out through a gap in the adventitia. Hence after stapling, the gap in the adventitia was sutured with 4-0 polypropylene to prevent a leak.

In this case, aggressive prehabilitation and detailed pre-operative planning including delineating anatomy with a CECT neck and being prepared for the dense adhesions helped in the patient undergoing an uneventful transcervical diverticulectomy and post-operative recovery.

## CONCLUSION

A cricopharyngeal diverticulum should be thought of in the differential diagnosis of the cause of globus pharyngeus when not responding to conservative measures of treatment. Adequate pre-operative preparation will aid in a smooth recovery.

## Ethical approval

The Institutional Review Board has waived the ethical approval for this study.

## Declaration of patient consent

The authors certify that they have obtained all appropriate patient consent.

## Financial support and sponsorship

Nil.

## Conflicts of interest

There are no conflicts of interest.

## Use of artificial intelligence (AI)-assisted technology for manuscript preparation

The authors confirm that there was no use of artificial intelligence (AI)-assisted technology for assisting in the writing or editing of the manuscript and no images were manipulated using AI.

## REFERENCES

1. Lee BE, Kim GH. Globus pharyngeus: A review of its etiology, diagnosis and treatment. *World J Gastroenterol* 2012;18:2462-71.
2. Jones D, Prowse S. Globus pharyngeus: An update for general

- practice. *Br J Gen Pract* 2015;65:554-5.
3. Ekberg O, Nylander G. Lateral diverticula from the pharyngo-esophageal junction area. *Radiology* 1983;146:117-22.
4. Orzell S, Falcone T, Grillone G. Killian-Jamieson diverticulum: A case report and argument for transcervical diverticulectomy. *J Otolaryngol Rhinol* 2016;2:2-5.
5. Ujiiie N, Taniyama Y, Sato C, Kamei T. Surgical intervention for Laimer's diverticulum, a rare type of pharyngoesophageal diverticulum: A case report. *OTO Open* 2019;3:247.
6. Killian G. About the mouth of the esophagus. *Magazine for Otology* 1908;55:1-44.
7. Jamieson EB. *Illustrations of regional anatomy*. Edinburgh: E. & S. Livingstone Ltd.; 1934. p. 44.
8. Haddad N, Agarwal P, Levi JR, Tracy JC, Tracy LF. Presentation and management of Killian Jamieson diverticulum: A comprehensive literature review. *Ann Otol Rhinol Laryngol* 2020;129:394-400.

**How to cite this article:** Iype GR, Jacob B, Titus DJ, Philip S. An unusual etiology of Globus pharyngeus – the Killian–Jamieson diverticulum. *Glob J Health Sci Res.* 2024;2:134-7. doi: 10.25259/GJHSR\_19\_2023